

FRACTURE-SEPARATION OF ARTICULAR CARTILAGE IN THE ADULT KNEE

C. JOHNSON-NURSE, D. J. DANDY

From Addenbrooke's Hospital, Cambridge

Seventy-six knees with fracture-separations of articular cartilage are described. The lesion involved the full thickness of the articular surface with exposed subchondral bone in 28 knees and only part of the thickness in 48. The clinical features and distribution of the lesions within the knee are described.

Although lesions of the articular cartilage without involvement of bone have been described clinically (O'Donoghue 1966; Jackson and Dandy 1976; Dandy 1981) and experimentally (Kennedy, Grainger and McGraw 1966), the distribution and clinical features of such lesions have not been reported. In this study, 76 knees with acute articular cartilage lesions are described. Two distinct patterns of lesion were recognised; chondral separations that involved the full thickness of the articular cartilage down to subchondral bone (Fig. 1),

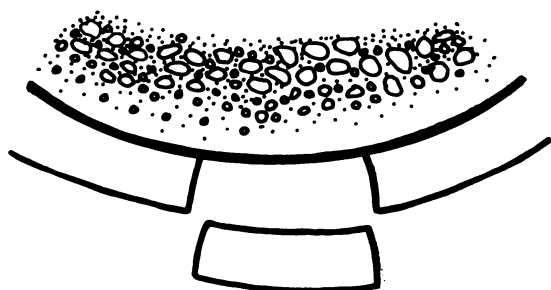


Fig. 1



Fig. 2

Figure 1—A full-thickness separation of articular cartilage extending down to subchondral bone. Figure 2—A partial thickness separation of articular cartilage with the fragment attached at one edge as a flap and without exposed subchondral bone.

and partial-thickness separations in which the fragment remained attached at one edge as a flap and the subchondral bone was not exposed (Fig. 2). The subchondral bone was intact and the lesions were therefore distinct from osteochondral fractures.

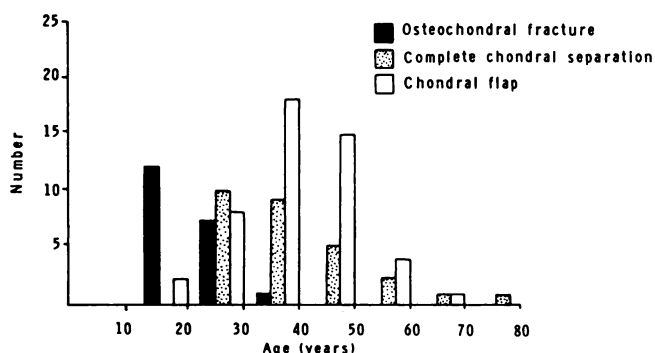


Fig. 3

Age distribution of the 72 patients (76 lesions) compared with that of the patients with osteochondral fractures reported by Matthewson and Dandy (1978).

PATIENTS AND METHOD OF STUDY

Between 1979 and 1982 articular cartilage lesions were found in 72 patients (51 men and 21 women) undergoing arthroscopy for the investigation of mechanical symptoms in the knee. Patients with osteoarthritis were excluded from the study. Both knees were examined in four patients to make a total of 54 knees in men and 22 in women. In one patient, both knees were examined under the same anaesthetic. The mean age was 37.1 years (men 35.5, women 41) with a range of 18 to 78 years (Fig. 3). The age distribution of the patients was compared with those of patients with osteochondral fractures of the lateral femoral condyle reported by Matthewson and Dandy (1978).

The symptoms and physical signs were recorded. All knees were examined arthroscopically and the site and character of the lesion noted. Full-thickness chondral separations with exposed subchondral bone were generally found to have vertical articular cartilage margins,

C. Johnson-Nurse, FRCS, Senior Registrar
D. J. Dandy, FRCS, Consultant Orthopaedic Surgeon
Addenbrooke's Hospital, Hills Road, Cambridge CB2 2QQ, England.
Requests for reprints should be sent to Mr D. J. Dandy.

© 1985 British Editorial Society of Bone and Joint Surgery
0301-620X/85/1033 \$2.00

Table I. Relationship of trauma to onset of symptoms

	Complete separation		Partial separation		Total knees	
	No.	%	No.	%	No.	%
Definite trauma	22	78	29	60	51	67
Possible trauma	3	11	4	8	7	9
No trauma	3	11	15	31	18	24

while partial-thickness lesions without exposed subchondral bone commonly had oblique or shelving margins. The presence of meniscal or ligamentous lesions also was recorded. Nine patients had previously undergone meniscectomy.

Treatment. Full-thickness separations of articular cartilage were treated by drilling the subchondral bone into underlying cancellous tissue to encourage healing (Pridie 1959; Insall 1967). Partial-thickness flaps were treated by debridement of the flap and removal of all loose tissue. Patients were told that they had a defect in their articular surface, that they had an increased chance of developing degenerative change in the joint in the future, and were advised to restrict their sporting activities accordingly.

FINDINGS

The presenting symptoms were pain in 72 knees (95%), swelling in 58 (76%) and locking in 14 (18%). In 47 patients (51 knees) there was a history of acute trauma, usually a twisting injury on the extended knee; seven patients, all engaged in competitive sport, could not recall any definite injury and 18 patients stated definitely that there had been no trauma to the knee. A history of definite trauma was more common in patients with full-thickness separation of the articular cartilage (Table I). **Distribution of the lesions.** There were 60 lesions of the medial femoral condyle and 16 of the lateral condyle, all in the area of weight-bearing in full extension. There were 28 full-thickness and 48 partial-thickness lesions. The ratio of partial-thickness to full-thickness lesions was 38 to 22 for the medial condyle and 10 to 6 for the lateral.

Associated lesions. Twelve knees had ruptured cruciate

ligaments (10 anterior and 2 posterior). Twelve patients had meniscal lesions (7 medial and 5 lateral). The articular cartilage fragment was found as a loose body in 21 knees.

The short-term results of operation were excellent, and study of the long-term results is in progress.

DISCUSSION

The matrix of hyaline articular cartilage contains a framework of collagen that is continuous with the collagen in the subchondral bone and this, together with ridging and grooving of the apposed surfaces of bone and articular cartilage, resists shear forces at the osteochondral junction. With increasing age the basal layers of articular cartilage become calcified, and a line develops separating calcified from non-calcified cartilage. This line, which has been likened to a tidemark (Fawns and Landells 1953; Landells 1957), provides a plane of weakness along which separation can occur and moves further from the subchondral bone with increasing age.

Osteochondral fractures are predominantly an injury of adolescents and young adults (Rosenberg 1964; Puddu and Mariani 1977; Matthewson and Dandy 1978) which suggests that in the younger patient the bond between articular cartilage and subchondral bone is stronger than the bone itself, and that with increasing age the plane of weakness becomes more superficial.

In this study, articular cartilage lesions were most commonly seen during the fourth decade of life, full-thickness separation being commoner in the younger patients. Full-thickness chondral separations were seen most commonly in the third decade of life and a history of definite trauma was more often seen in these patients than in those with a partial-thickness lesion. Apart from the absence of a definite history of true mechanical locking of the knee, the symptoms were very similar to those of a meniscal tear. Fracture-separations of articular cartilage should therefore be included in the differential diagnosis of any meniscal lesion and should be considered a likely diagnosis if the symptoms began with a twisting movement on the almost fully extended knee, and were not followed by true mechanical locking.

REFERENCES

Dandy, DJ. *Arthroscopic surgery of the knee.* Edinburgh, London, New York: Churchill Livingstone, 1981.

Fawns HT, Landells JW. I. Histochemical studies of rheumatic conditions: observations on fine structures of the matrix of normal bone and cartilage. *Ann Rheum Dis* 1953;12:103-13.

Insall JN. Intra-articular surgery for degenerative arthritis of the knee: a report of the work of the late K. H. Pridie. *J Bone Joint Surg [Br]* 1967;49-B:211-28.

Jackson RW, Dandy DJ. *Arthroscopy of the knee.* New York: Grune & Stratton, 1976.

Kennedy JC, Grainger RW, McGraw RW. Osteochondral fractures of the femoral condyles. *J Bone Joint Surg [Br]* 1966;48-B:436-40.

Landells JW. The reactions of injured human articular cartilage. *J Bone Joint Surg [Br]* 1957;39-B:548-62.

Matthewson MH, Dandy DJ. Osteochondral fractures of the lateral femoral condyle: a result of indirect violence to the knee. *J Bone Joint Surg [Br]* 1978;60-B:199-202.

O'Donoghue DH. Chondral and osteochondral fractures. *J Trauma* 1966;6:469-81.

Pridie KH. A method of resurfacing osteoarthritic knee joints. *J Bone Joint Surg [Br]* 1959;41-B:618-9.

Puddu G, Mariani P. Osteochondral fractures of the knee. *Ital J Orthop Traumatol* 1977;Suppl 3:129-37.

Rosenberg NJ. Osteochondral fractures of the lateral femoral condyles. *J Bone Joint Surg [Am]* 1964;46-A:1013-26.